



## Intrahepatic Glissonian access for segmental liver resection in cirrhotic patients

Marcel Autran C. Machado, M.D.<sup>a,b,\*</sup>, Paulo Herman, M.D.<sup>a</sup>, Estela R.R. Figueira, M.D.<sup>b</sup>,  
Telesforo Bacchella, M.D.<sup>b</sup>, Marcel C.C. Machado, M.D., F.A.C.S.<sup>a,b</sup>

<sup>a</sup>Department of Abdominal Surgery, Cancer Hospital, Rua Evangelista Rodrigues 407-05463-000, São Paulo, Brazil

<sup>b</sup>Department of Surgery, University of São Paulo, São Paulo, Brazil

Manuscript received September 14, 2005; revised manuscript January 1, 2006

### Abstract

The main goal of segmental technique is to preserve the maximum amount of liver parenchyma. Liver-preserving techniques are especially important for patients with hepatocellular carcinoma and cirrhosis. We report the technique for segmental liver resection in cirrhotic patients and detail technical difficulties and immediate surgical outcome. For right segmental liver resections the intrahepatic access is performed through small incisions around the hilar plate. Left segmental resection technique also consists of small incisions following specific anatomic landmarks. Nineteen cirrhotic patients underwent segmental liver resections. A blood transfusion was required in 2 patients. No patient experienced major bleeding from the liver incisions made for intrahepatic access. The median hospital stay was 5 days. No surgical mortality occurred. The intrahepatic access technique allows individual resections of liver segments and is feasible even in cirrhotic patients. Knowledge of segmental liver resection techniques is an essential armamentarium in the modern era of liver surgery. © 2006 Excerpta Medica Inc. All rights reserved.

**Keywords:** Liver resection; Segmental; Glissonian pedicle, Cirrhosis; Liver anatomy

Hepatic resection is considered the optimal treatment for primary and secondary liver tumors, however, in patients with hepatocellular carcinoma, because of the high incidence of cirrhosis and the inability of the diseased liver to sustain parenchymal reduction and surgical trauma, resection may be limited.

Wedge resections have been used as a tissue-preserving technique for cirrhotic patients, however, its drawback is that it may produce a fracture between the tumor and the surrounding liver tissue, which results in positive margins in up to 30% of the patients even in experienced surgeons' hands [1]. According to some investigators, anatomic segmental hepatic resection has better results than wedge resection as an oncologic surgery for both hepatocarcinoma and colorectal liver metastases [2,3].

The knowledge of liver anatomy and advances in imaging technology have made segmental anatomic liver resections easier by reducing intraoperative bleeding and by

providing adequate margins and a low rate of postoperative complications [4–6]. Launois and Jamieson [7] described an intrahepatic access to right Glissonian pedicles that involves major hilar plate dissection, blunt digital maneuvers, and hilar clamping that may be hazardous in cirrhotic livers. We recently reported an intrahepatic access for both right and left segmental liver resections that allows the removal of individual hepatic segments [8,9]. These techniques were used mainly in patients with normal livers. With the improvement of experience the indications were expanded for cirrhotic patients. In this article we report the segmental liver resection technique in cirrhotic patients and detail the technical difficulties and immediate surgical outcome.

### Technique

#### *Preoperative evaluation and patient selection*

Preoperative investigation included liver and renal function tests, complete blood count, and coagulation profile.

\* Corresponding author. Tel.: +55-11-3289-1188; fax: +55-11-3289-1188.

E-mail address: dr@drmarcel.com.br

All patients underwent an abdominal computed tomography scan and/or magnetic resonance imaging. Patients with Child-Pugh's class A cirrhosis and small hepatocellular carcinoma occupying no more than 2 liver segments were selected for liver resection. The segmental approach was used whenever an adequate margin of at least 1 cm could be anticipated.

### Surgical technique

A bilateral subcostal incision extended superiorly in the midline to the xyphoid was performed and the liver was mobilized in a standard fashion. Intraoperative ultrasound evaluation was performed in every patient. For right segmental liver resection the intrahepatic access was performed through 3 small incisions around the hilar plate as previously described [8]. A small anterior incision was made in front of the hilum to disclose the anterior surface of the right hepatic pedicle. A second incision was made perpendicular to the hepatic hilum in segment VII and a third incision was made on the right edge of the gallbladder bed (Fig. 1). A large curved Mixer clamp was inserted through the incisions to approach either the anterior or posterior sectors' Glissonian pedicles (Figs. 2 and 3). To access each segment's Glissonian pedicle of the right liver to perform unisegmentectomies V, VI, VII, or VIII, further blunt dissection deep in the parenchyma was needed (Fig. 4). Once identified (Fig. 4A), the right posterior pedicle was dissected on its anterior surface for 10 to 15 mm where it was possible to identify bifurcation of segments VI and VII (Figs. 4B and 4C). At this time each segmental pedicle from segments VI or VII could be encircled individually (Fig. 4C, small arrow) and clamped, result-

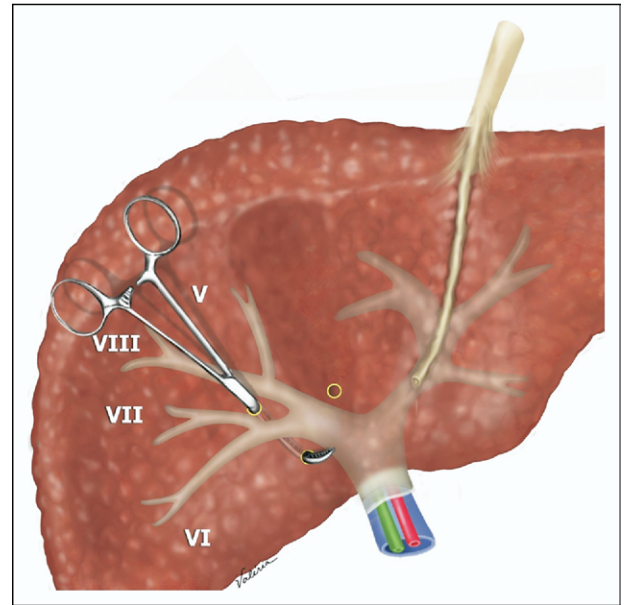


Fig. 2. Intrahepatic Glissonian access of the right posterior pedicle (containing arterial, portal, and bile duct branches of segments VI and VII).

ing in ischemic delineation of the segment (Figs. 4D and 5). The same maneuver can be used to identify the Glissonian pedicles of segments V and VIII.

For left segmental resections, the technique also consists of small liver incisions following specific anatomic landmarks such as the Arantius and round ligaments [9]. On the left liver it is possible to individually reach any segment pedicles without deep parenchymal dissection. With 3 small incisions it is possible to reach the pedicles of segments II and III (Fig. 6). The first incision was made on the left margin of the round ligament, the second behind the caudal portion of the Arantius ligament, and the third midway

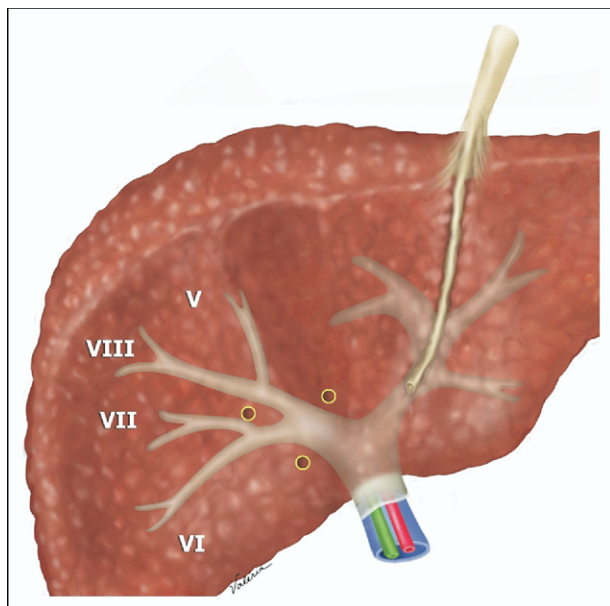


Fig. 1. Incisions used for intrahepatic access of right liver Glissonian pedicles (segments V, VI, VII, and VIII).

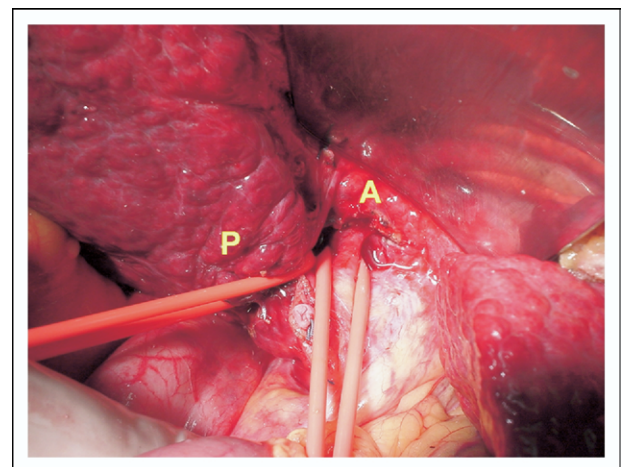


Fig. 3. Intrahepatic access for right segmental resection. A, Right anterior Glissonian pedicle (containing arterial, portal, and bile duct branches of segments V–VIII). P, Right posterior Glissonian pedicle (containing arterial, portal, and bile duct branches of segments VI–VII).

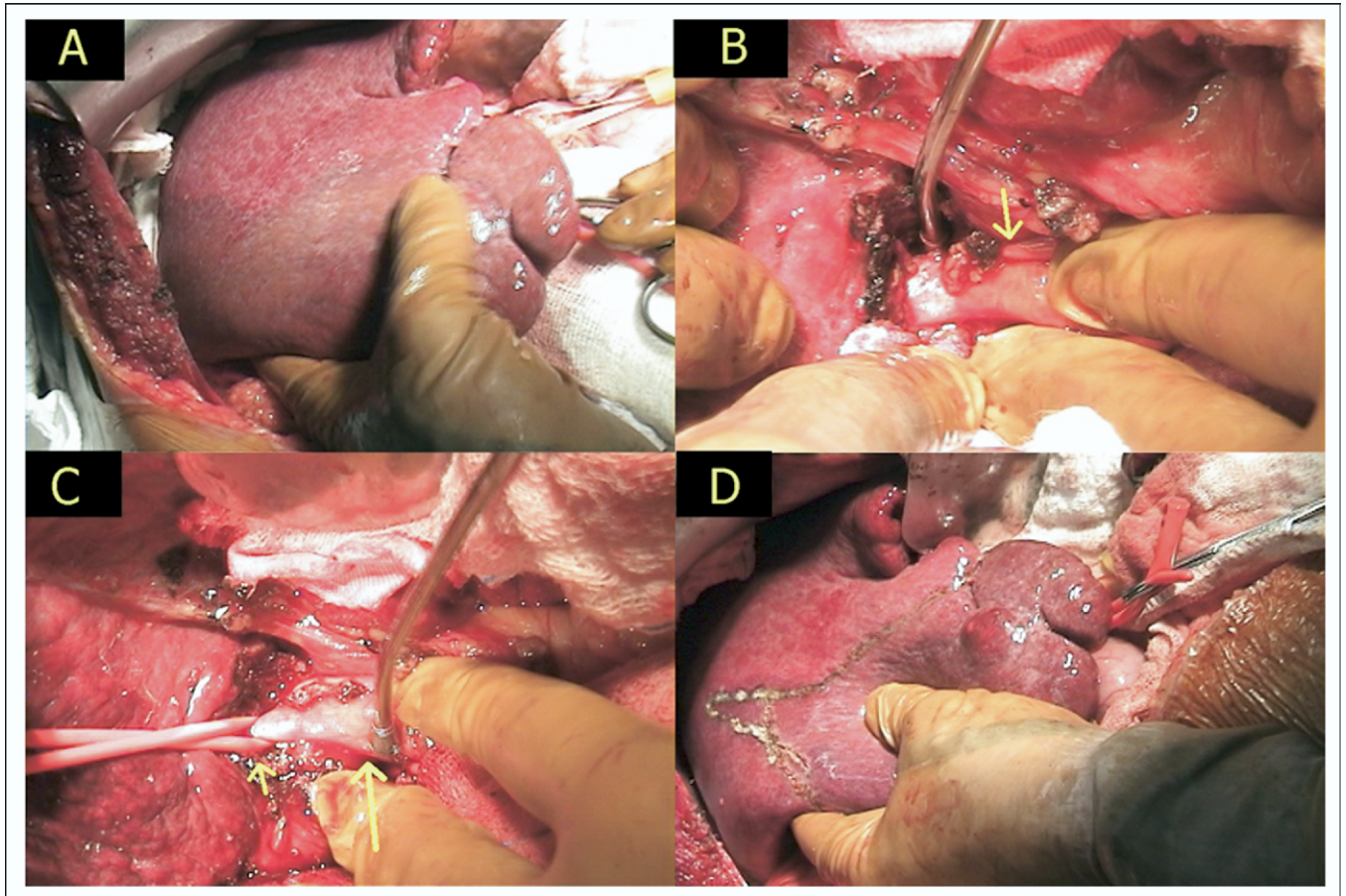


Fig. 4. Step-by-step technique for unisegmentectomy on the right liver. (A) The posterior sector Glissonian pedicle is identified and clamped, resulting in ischemic delineation of segments VI and VII. (B) The posterior sector pedicle (arrow) is pulled downward and further blunt dissection on its anterior surface is performed. (C) After about 10 to 15 mm of blunt dissection over the posterior sector pedicle (large arrow), it is possible to see the emergence of the segment VI Glissonian pedicle already encircled (small arrow). (D) The Glissonian pedicle from segment VI already is clamped, resulting in ischemic delineation of this segment. Note the irregular shape of segment VI, which probably is caused by the underlying cirrhosis.

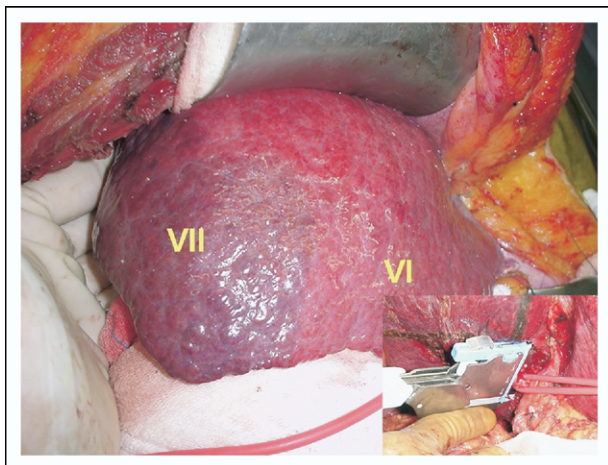


Fig. 5. Intraoperative view of segment VII ischemic delineation; segment VI is not ischemic. Inset: segment VII Glissonian sheath (containing arterial, portal, and bile duct branches of segment VII) is divided using a vascular stapling device.

between the first 2 incisions. A large Mixer was inserted through these incisions to encircle the Glissonian pedicles from segments II and/or III. Another 2 incisions were necessary to reach the segment IV pedicle (Fig. 6). One incision was made on the right margin of the round ligament and another was made in front of the hilum.

Once identified, the Glissonian sheath was tied and divided. The limits of the liver segment or segments became defined clearly through an ischemic delineation (Figs. 4A, 4D, and 5) and the liver parenchyma then was transected as usual. All these steps were performed without the Pringle maneuver.

## Results

Nineteen consecutive cirrhotic patients underwent the intrahepatic pedicle approach technique for segmental liver resections from September 2001 to February 2005. There were 11 men and 8 women, with a mean age of 61.8 years (range, 42–74 y). All patients had hepatocellular carcinoma and Child-Pugh's class A cirrhosis.

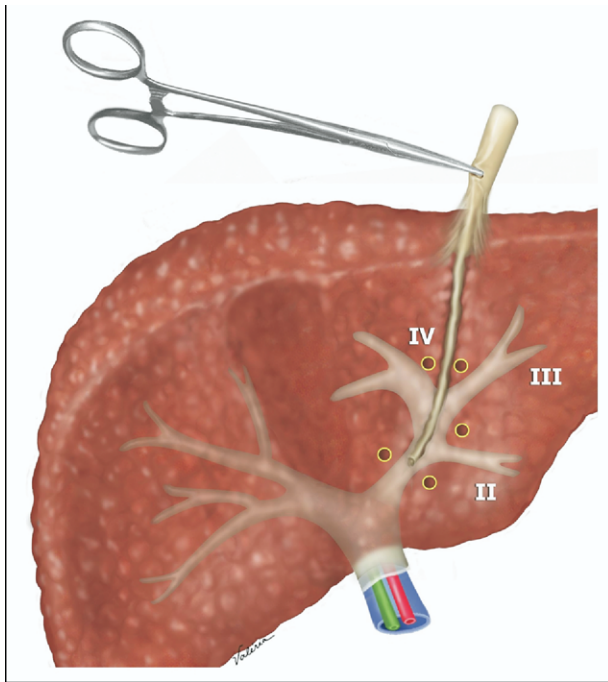


Fig. 6. Incisions used for the intrahepatic access of the left liver Glissonian pedicles.

Sixteen patients underwent unisegmentectomies: 6 had resection of segment VI (Fig. 4), 6 had resection of segment VII (Fig. 5), 2 had resection of segment III, 1 had resection of segment V, and 1 had resection of segment VIII. Three patients underwent bisegmentectomies: 2 had a bisegmentectomy of segments II–III and 1 had a bisegmentectomy of segments VI–VII.

A blood transfusion (mean, 2 U) was necessary in 2 patients (10.5%). No patient experienced major bleeding from the liver incisions made for intrahepatic access, and the mean surgical time was 227 minutes (range, 180–310 min). Preoperative and postoperative laboratory data are shown in Table 1. Eight patients (42.1%) developed postoperative ascites that required diuretics but had good outcome. There was no correlation between the amount of liver resected and the development of ascites. Despite the presence of cirrhosis, no patient developed postoperative liver failure and no surgical mortality occurred. The median hospital stay was 5 days (range, 5–8 d). All patients had free surgical margins at histologic evaluation.

## Comments

The main advantage of segmental resections is to allow the surgeon to tailor the extent of the resection to the extent of the tumor, preserving the maximum amount of liver parenchyma. This is of particular importance for patients with underlying cirrhosis. Moreover, because of the tendency of hepatocellular carcinoma to propagate through the portal vein [10], the removal of the entire territory of the feeding portal

pedicle is advisable and can be achieved by segmental resection.

Similar survival rates after segmental resections and hemihepatectomies have been reported [11–13]. In addition, some investigators have shown that the number of hepatic segments resected is the main predictor of perioperative morbidity and mortality [1,14].

Technical difficulties were encountered during the study and should be reported. In cirrhotic livers, incisions for intrahepatic access are prone to bleed and caution must be taken, these incisions must be located precisely to avoid larger wounds and further bleeding. There were no major difficulties to reach the Glissonian sheaths of segments VI and VII separately because they usually present early bifurcation near the hilar plate and their course may be apparent inside the incisura dextra of Gans [15]. The Glissonian sheaths of segments V and VIII may be located deep in the liver parenchyma, hence further dissection is needed and may cause bleeding. A possible alternative to the anatomic removal of segments V or VIII is the temporary clamping of the right anterior pedicle and proceeding with the resection of segments V or VIII (resection under right anterior sector inflow control). The limits of those segments can be estimated by dividing the liver anterior sector exactly in the middle. The same strategy can be used if one experiences any difficulty reaching segments' VI or VII Glissonian pedicles. For left liver segmental resections we did not find any difficulty in identifying the Glissonian pedicle of segments II and III individually.

In bisegmentectomies VI–VII or V–VIII the technique is appropriate once the retrieval of the pedicles of right anterior and posterior sectors is not difficult to obtain [8,16], however, right inferior (V–VI) or superior (VII–VIII) bisegmentectomies involve dissection inside the hilar plate deep in the parenchyma, which may be hazardous in cirrhotic patients.

Our data showed that the inflow control achieved by the Glissonian approach resulted in limited bleeding whereas only 2 of our patients required a blood transfusion. Regard-

Table 1  
Mean preoperative and postoperative (third day) laboratory data

	Preoperative (mean $\pm$ SD)	Third postoperative day (mean $\pm$ SD)
Hemoglobin level (g/dL)	14.0 $\pm$ 1.1	11.4 $\pm$ 1.7
Hematocrit level (%)	41.2 $\pm$ 4.0	34.7 $\pm$ 4.6
Aspartate transaminase level (U/L)	72.4 $\pm$ 50.7	206.6 $\pm$ 150
Alanine transaminase level (U/L)	86.8 $\pm$ 55.8	245.8 $\pm$ 271.4
Total bilirubin level (mg/dL)	.9 $\pm$ .3	1.2 $\pm$ .5
Albumin level (g/dL)	4.2 $\pm$ .5	3.4 $\pm$ .3
Prothrombin time (international normalized ratio)	1.2 $\pm$ .2	1.8 $\pm$ .3
Alkaline phosphatase level (U/L)	99.4 $\pm$ 36.2	74 $\pm$ 8.6
Gammaglutamyltransferase level (U/L)	121.8 $\pm$ 69.4	82.5 $\pm$ 50.1

n = 19.

ing vascular control, minimizing bleeding is crucial because blood loss seems to affect both short- and long-term outcomes after liver resection [17]. In our series, the morbidity was represented mainly by postoperative ascites, which were managed easily with diuretics. No major complications were observed and the median hospital stay was short, probably owing to the preservation of liver function, a consequence of tissue-preserving resection without the Pringle maneuver.

Segmental liver resection with the proposed technique is feasible even in cirrhotic patients. Segmental inflow control (right anterior or posterior sector clamping) is easy to achieve with the proposed technique and can be used to perform individual resections of right liver segments. The knowledge of segmental liver resection techniques is essential in the modern liver surgery context.

## References

- [1] Jarnagin WR, Gonen M, Fong Y, et al. Improvement in perioperative outcome after hepatic resection: analysis of 1,803 consecutive cases over the past decade. *Ann Surg* 2002;236:397–406.
- [2] De Matteo RP, Palese C, Jarnagin WR, et al. Anatomic segmental hepatic resection is superior to wedge resection as an oncologic operation for colorectal liver metastases. *J Gastrointest Surg* 2000;4:178–84.
- [3] Yamamoto M, Takasaki K, Ohtsubo T, et al. Effectiveness of systematized hepatectomy with Glisson's pedicle transection at the hepatic hilus for small nodular hepatocellular carcinoma: retrospective analysis. *Surgery* 2001;130:443–8.
- [4] Couinaud C. *Le Foie: Études Anatomiques et Chirurgicales*. New York: Masson Publishers; 1957.
- [5] Gazelle GS, Haaga JR. Hepatic neoplasms: surgically relevant segmental anatomy and imaging techniques. *AJR Am J Roentgenol* 1992;158:1015–8.
- [6] Billingsley KG, Jarnagin WR, Fong Y, et al. Segment-oriented hepatic resection in the management of malignant neoplasms of the liver. *J Am Coll Surg* 1998;187:471–81.
- [7] Launois B, Jamieson GG. The posterior intrahepatic approach for hepatectomy or removal of segments of the liver. *Surg Gynecol Obstet* 1992;174:155–8.
- [8] Machado MA, Herman P, Machado MC. A standardized technique for right segmental liver resections. *Arch Surg* 2003;138:918–20.
- [9] Machado MA, Herman P, Machado MC. Anatomical resection of left liver segments. *Arch Surg* 2004;139:1346–9.
- [10] Yamamoto J, Kosuge T, Takayama T, et al. Recurrence of hepatocellular carcinoma after surgery. *Br J Surg* 1996;83:1219–22.
- [11] Kosuge T, Makuuchi M, Takayama T, et al. Long-term results after resection of hepatocellular carcinoma: experience of 480 cases. *Hepatogastroenterology* 1993;40:328–32.
- [12] Okada S, Shimada K, Yamamoto J, et al. Predictive factors for postoperative recurrence of hepatocellular carcinoma. *Gastroenterology* 1994;106:1618–24.
- [13] Redaelli CA, Wagner M, Krahenbuhl L, et al. Liver surgery in the era of tissue-preserving resections: early and late outcome in patients with primary and secondary hepatic tumors. *World J Surg* 2002;26:1126–32.
- [14] Chouillard E, Cherqui D, Tayar C, et al. Anatomical bi- and trisegmentectomies as alternatives to extensive liver resections. *Ann Surg* 2003;238:29–34.
- [15] Reynaud BH, Coucoravas GO, Giuly JA. Basis to improve several hepatectomy techniques involving the surgical anatomy of incisura dextra of Gans. *Surg Gynecol Obstet* 1991;172:490–2.
- [16] Machado MA, Herman P, Meirelles RF Jr, et al. How I do it: bi-segmentectomy V-VIII as alternative to right hepatectomy: an intrahepatic approach. *J Surg Oncol* 2005;90:43–5.
- [17] Nonami T, Nakao A, Kurokawa T, et al. Blood loss and ICG clearance as best prognostic markers of post-hepatectomy liver failure. *Hepatogastroenterology* 1999;46:1669–72.